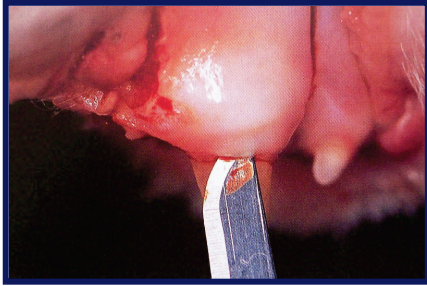


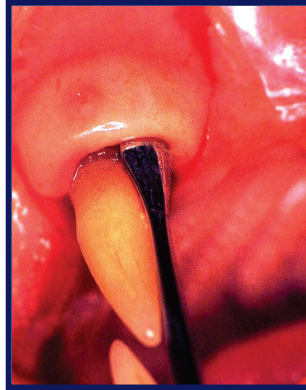
Surgical Extraction of Canine (Fang) Tooth in the Cat

Surgical Extraction of feline teeth requires careful and exact technique as these teeth can more easily be damaged, leaving pieces of root behind. Cats also often have resorptive lesions on their teeth, which makes them brittle and difficult to remove. Bone graft material is often used in cats to fill the empty tooth socket to help with healing and strengthen the jaw bone.

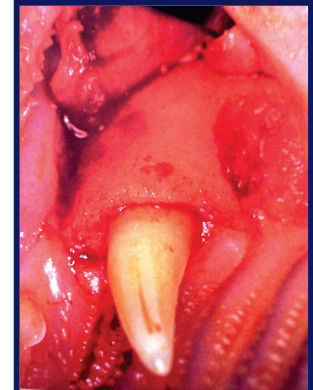
The following is an outline of a surgical extraction of the upper fang tooth in a cat:



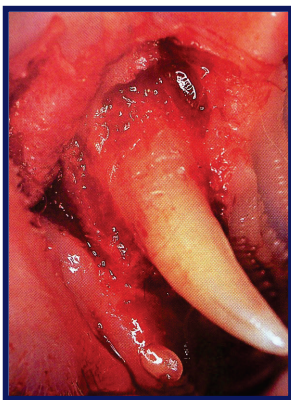
Incision around the gumline to loosen the gum tissue to create a flap



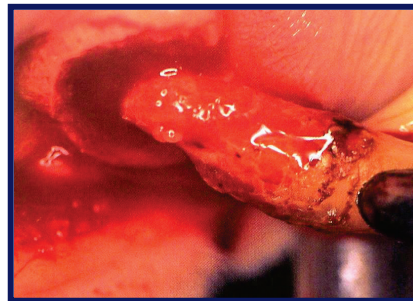
Loosening of the gum flap with a dental elevator tool



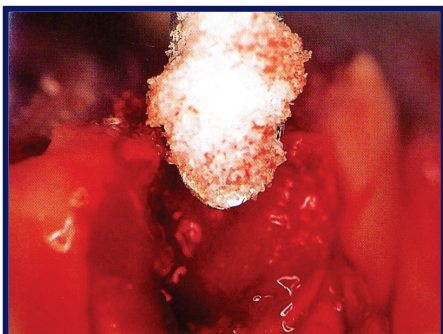
The flap is pulled back to expose the jaw bone over the tooth root



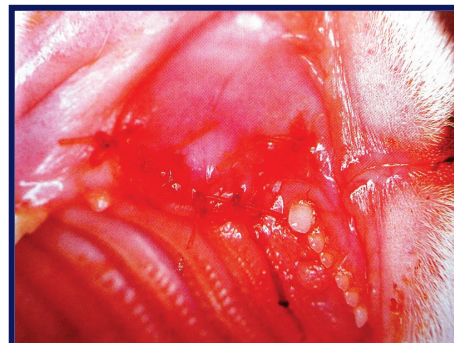
Removal of jaw bone around the tooth root with a dental drill



Careful loosening of the root and extraction of the tooth with a dental elevator tool



Placement of Consil™, a bone graft material, into the tooth socket in order to facilitate healing



The gum flap is replaced over the tooth socket and sutured in place